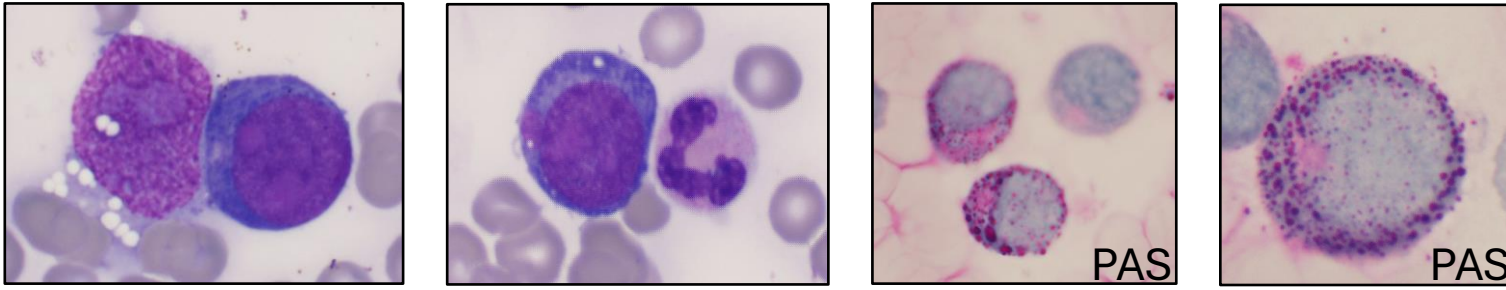
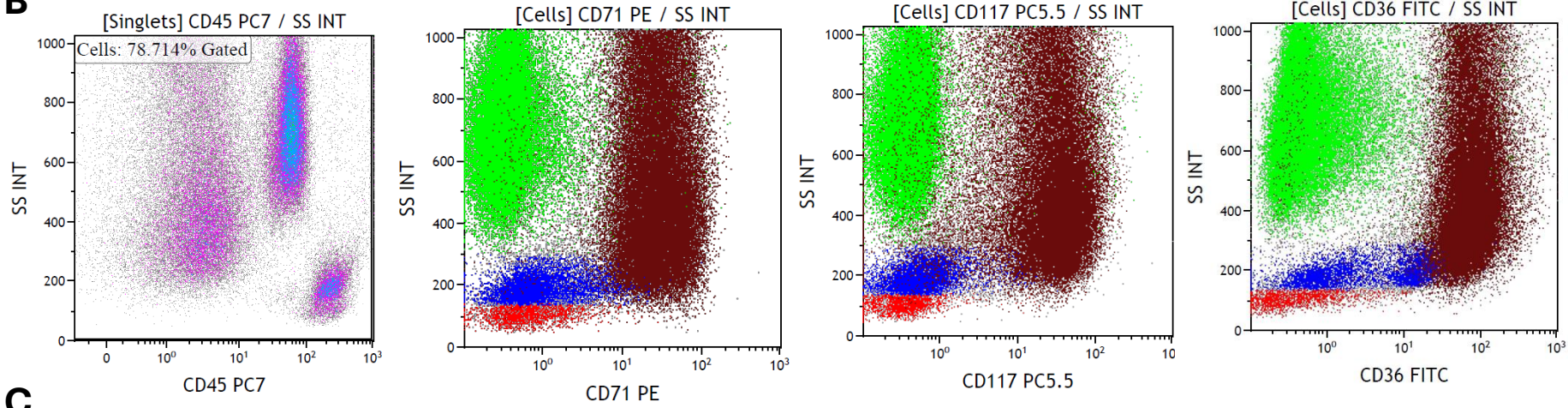


A

Legend:
 Panel A : Two bone marrow morphology images showing the blast like cells and two PAS stains showing block positivity.
 Panel B : Flow Cytometry plots.
 Panel C : Immunohistochemistry stains showing H&E, cytokeratin,CD117 and EMA.

B**C**